

This is an open-access article distributed under the terms of the Creative Commons Attribution License, which permits unrestricted use, distribution, and reproduction in any medium, provided the original author(s) and source are credited.



ISSN: 0974-8369

Biology and Medicine

International, Open Access

Available online at: www.biolmedonline.com

This article was originally published in this journal and the attached copy is provided for the author's benefit and for the benefit of the author's institution, for commercial/research/educational use including without limitation use in instruction at your institution, sending it to specific colleagues that you know, and providing a copy to your institution's administrator.

All other uses, reproduction and distribution, including without limitation commercial reprints, selling or licensing copies or access, or posting on open internet sites, your personal or institution's website or repository, are requested to cite properly.

Analysis of Morpho-Functional Characteristics of Uterine Horns in Ovarian Sclerosis

Khassanova Madina Asilhanovna^{1*}, Tegza Alexandra Alekseevna¹, Tegza Ivan Mikloshevich¹, Mustafin Muafik¹, Aniulienė Albina²

¹Kostanai State University A. Baitursynov, Kostanay, Kazakhstan

²Pathology Center, Veterinary Academy, Lithuanian University of Health Sciences, Kaunas, Lithuania

Abstract

The epithelial tissue of the reproductive organs in all animal species plays a critical role in the reproductive function. In the reproductive tract organs, epithelium not only serves as a protective tissue, but also enables the function of specific secretion. They provide the environment for the existence of gametes and embryos and enable active kinetic processes that contribute to the transfer of reproductive cells to the fertilization target. According to many researchers, the most common cause of symptomatic infertility in cows is the functional disorders of the ovaries. However, there is little research dedicated to functional and morphological analysis of cell-tissue substrate using modern histochemical and morphometric techniques allowing, along with modern methods, to carry out an objective assessment of the reproductive system. Therefore, the study of etiology, pathogenesis, pathomorphology and development of the effective methods of treatment and prevention of ovarian dysfunction in productive animals is of great importance in the organization of modern livestock with intensive use of cows and heifers for reproduction. Quite a number of researches have established that the histological and morphological changes in the uterine horns of cows are correlated with changes in the ovaries. In particular, for ovarian sclerosis, the functional activity of cells in the epithelium of uterine horns is degraded.

Key words

Ovary; Sclerosis; Pathology; Pathomorphology

Introduction

The contemporary literature data indicate significant species peculiarities of structural and functional organization of the epithelium in the reproductive tract organs. Despite a rather large number of studies on the physiology and pathology of the reproductive system of cattle, there are still no formulated concepts that would establish a specific significance of epithelial tissue in the physiology of reproduction, etiology and pathogenesis of diseases of the reproductive system and infertility of animals.

Measures of morphological and functional status of the epithelial tissue are not used adequately for timely diagnosis and prognosis of the pathology of reproductive function. This is due to the lack of available methods for the preparation of material for research, as well as the main criteria for the assessment of epithelial tissue in various diseases.

Modern endocrinology of reproduction indicates that epithelial tissue is a highly sensitive and specific criterion of bioassay of healthy and unhealthy reproductive system status. The national and foreign literature scarcely covers the informative importance of histo- and cytological criteria of epithelial tissue in the reproduction system organs of cows for theoretical and practical issues of reproduction, for the study of physiology and pathology of the reproductive function.

Methods of diagnosis, treatment and prevention of disorders of postpartum recovery of ovarian functional activity are some of the main problems in animal reproduction [1].

The study of functional morphology of healthy and unhealthy reproductive organs of farm animals is one of the most complex and urgent problems of biology and veterinary medicine.

However, the causes and methods of recovering fertility in replacement heifers with ovarian hypofunction in specialized cattle breeding facilities are not well studied to date. The national and foreign literature contains no information on the distribution of ovarian

hypofunction; anatomical and morphological changes in the genital organs have been little studied; there is no material on the comparative effectiveness of the different methods of recovering fertility in heifers for this pathology [2,3].

Ovarian pathology takes a significant part in the symptomatic infertility of cattle. To date, a vast material has been generated covering the complexity and diversity of the causes leading to infertility in cows due to ovarian pathology.

Various researches on the problems of ovarian pathology in cows are sparse and sometimes contradictory; therefore, in our opinion, the problems of their generalization and analysis based on modern concepts are important. There are several classifications of pathological states of ovaries in cows. The main difference between them lies in how the damaging agent is acting.

Ovarian sclerosis is characterized by the replacement of their parenchyma with connective tissue. The disease occurs in 3.8-6.5% of the number of infertile cows.

Scientific novelty. The causes and factors affecting the reproductive disorders in cows in the Kostanai region, Kazakhstan, are examined. It is given detailed morfofunkcionalnaja, histologic and morphometric characteristics of ovarian and endometrial cancer. A close correlation of the ovaries and uterus is determined in the study.

Ovarian sclerosis refers to the inflammation of ovaries and interstitial tissue with its subsequent hyalinization.

*Corresponding author: Khassanova Madina Asilhanovna, Kostanai State University A. Baitursynov, Kostanay, Kazakhstan.

Received: Nov 8, 2015; Accepted: Dec 9, 2015; Published: Jan 10, 2016

Citation: Asilhanovna KM, Alekseevna TA, Mikloshevich TI, Muafik M, Albina A (2016) Analysis of Morpho-Functional Characteristics of Uterine Horns in Ovarian Sclerosis. Biol Med (Aligarh) 7(5): BM-144-16, 6 pages.

Copyright: © 2016 Asilhanovna et al. This is an open-access article distributed under the terms of the Creative Commons Attribution License, which permits unrestricted use, distribution, and reproduction in any medium, provided the original author and source are credited.

Under the influence of one of these or other factors begins an enhanced growth of the connective tissue of the ovary, which exerts constant pressure on the parenchyma and stroma causing their atrophy. Connective tissue is then hyalinized with the formation of dense foci around the ovary or on its separate areas. Tunica albuginea becomes strongly densified and follicles stop from forming in the ovaries. Reproductive cycle is disrupted or even stops. If the proliferation of connective tissue is caused by an injury of the ovary, the connective tissue grows in the place of injury, and the second ovary can function normally. The ovaries are reduced in size, have a dense, even stony consistency and their surface is uneven. With intense development of connective tissue, ovaries may be increased in size. Maturing follicles, corpus luteum or cysts are not present in the ovaries. Over time, uterine atony develops and then it atrophies. Then permanent infertility sets in [4].

Because of this, we believe it necessary to study the morphological and functional changes in the uterus with ovarian dysfunction.

In the present research we will analyze the dynamics of functional activity (cytometric characteristics) of glandular and surface epithelium of the uterine horns in cows with infertility due to ovarian sclerosis.

The outcomes will allow assessing the functional capacity of the mucous membrane of the uterine horns, which is necessary to assess the depth of structural changes with this pathology.

Scientific novelty and practical significance. The problem of farm animal infertility is multifaceted. The scientific literature widely covers the degree of knowledge about disorders in the mature organism to reproduce [5–13]. However, postpartum pathology has to be studied further. First of all, we need to select the exact guidelines for assessing the physiological status of the genital organs of cows.

Therefore, matters connected with the study of morphological characteristics of clinically healthy cows and pathology of the reproductive organs, as well as the development of methods of diagnosis and treatment of these processes, is an important task that will allow revealing the causes of mass infertility in cows, as well as preventing it.

Research goal and objectives. The goal of our research was to study the morphological and functional characteristics of the reproductive organs of cows with ovarian dysfunction because of their sclerosis.

To achieve this goal, the following objectives were set:

1. Identify the main causes of cow disposal due to impaired reproductive function.
2. Study the pathological, histological characteristics of the mucous membrane of uterine horns in cows with ovarian dysfunction.
3. Study the morpho-functional characteristics of glandular and surface epithelium of the uterine horns in cows with infertility due to ovarian sclerosis.

Materials and Methods

In order to identify the main causes of cow disposal in Kostanay region, we studied the content of veterinary and livestock reports on the causes of culling cattle in the farms. On the basis of the information we collected, we identified the category of cows to be culled due to gynecological diseases.

Sets of genitals of 60 cows from 4 to 7 years old were used as a basis for the differential diagnosis of diseases.

To identify morphometric parameters, a fresh material was used to determine the total mass of individual organs (oviducts, ovaries, horns,

body with the help of the measuring thread and calipers and cervix). Weighing was performed on laboratory and torsion scales VT-500 up to 0.001 g. Linear indicators of organ parts were measured with an accuracy of 1.0 mm.

We used the following research methods:

1. histological, morphometric, linear study of tissues of the reproductive system of clinically healthy cows and cows with pathology (10% formol-fixation, paraffin embedding, hematoxylin and eosin stain, sirius red stain, cytometry).
2. work with equipment for preparation, embedding, staining of histological sections (Thermo scientific tissue processor, tissue embedding system TES 99 Medite medizintechnik, semi-automatic rotary microtome Accu-cut SRM, slide stainer Tissue-Tek DRS). For identifying the functional activity of epithelial cells, the area of the surface and glandular epithelium and their nuclei, nuclear-cytoplasmic ratio of epithelial cells by an imaging analysis computer program were determined.

Digital material was processed statistically using the Excel 2010 computer program. Figures and diagrams were compiled based on the results of the research.

Results and Discussion

On the basis of the studies of biological material derived from cows with reproductive dysfunction, it was found that the pathological changes identified in the genital organs of cattle caused the failure of reproductive function in cows.

The highest percentage of pathology in cows accounts for endometritis (32.8%) and ovarian pathology (31.2%). Reproductive disorders in 23.3% of the animals are associated with obesity. Infantilism and inflammation of oviducts cause infertility in 12.5 and 1.5% of the total number of animals examined respectively.

Morphometric studies of ovarian and uterine horns in cows

The ovaries of cows are paired glands of oval form, elastic consistency, from pale sand to gray-white color.

The length and width of the left ovary with sclerotization of cortex and medulla were 3.06 ± 0.46 and 2.23 ± 0.05 cm. The length of the right ovary with this pathology was 3.46 ± 1.44 cm, width – 2.44 ± 0.23 cm.

The analysis of morphometric studies of ovaries and uterine horns in cows identified that the average mass of the left ovary was 7.33 ± 1.25 g, right ovary – 5.08 ± 0.52 g.

The average mass of the left and right horns was 38 ± 38.6 and 38.5 ± 32.2 g respectively.

With the proliferation of the connective tissue, the quantity of follicles in the left ovary ranged from 6 to 21, in the right number – from 5 to 14. Moreover, they develop only on one third of the medulla of ovaries, which is associated with the ingrowth of the connective tissue in the medulla and cortex across the greater area of the ovary.

The histologic examination resulted in 63.2% of primary follicles and 36.8% of secondary follicles in the medulla of the left ovary. Left ovary usually undergoes a significant ingrowth of connective tissue: 82.5% of primary, 13.7% of secondary, and 2.5% of mature follicles were identified across the thickness of the preserved tissue of the medulla of

1 right ovary. Atretic follicles were also noticed (1.25%). No corpora lutea
2 in the ovaries were found.

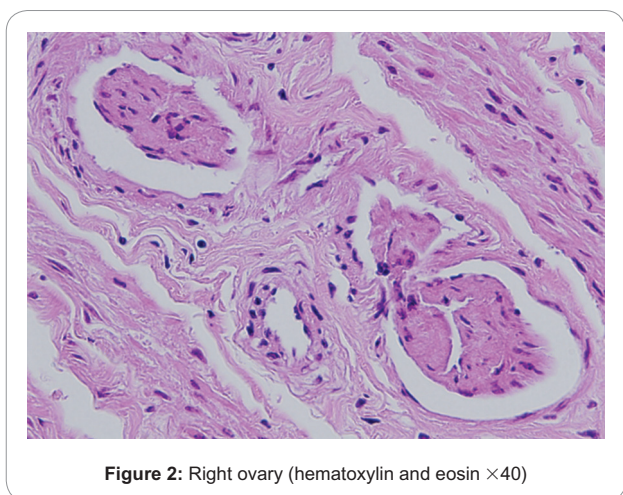
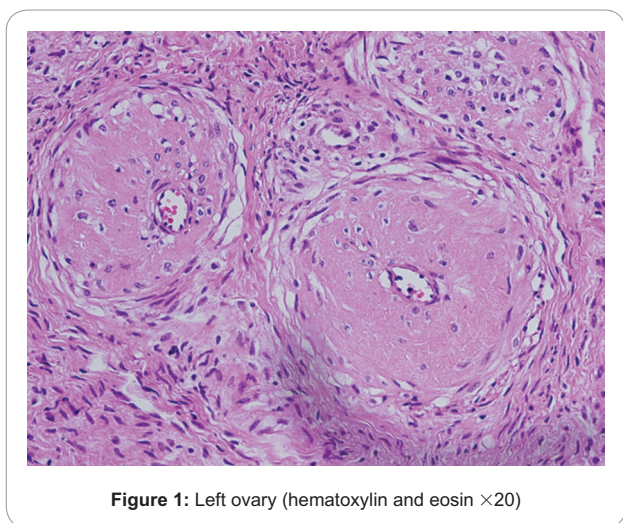
3 To identify the average functional activity, a cytometric character-
4 ization of follicular epithelium was carried out with the cytometric
5 studies of follicles at different stages of development.

6
7 Histological examination of some samples revealed the following
8 changes. In the left and right ovaries, it was seen that the follicular wall is
9 lined with epithelial cells. Signs of sclerotization in the form of invading
10 connective tissue fibers were detected in the parenchyma of the ovary.
11 The preparation demonstrates the ovary with signs of medulla sclerosis
12 (Figures 1 and 2).

13 There is a significant number of microvessels. Typical interstitial
14 cells are preserved only in some areas. There are some large cells with
15 vacuolated cytoplasm. Connective tissue fibers are seen over a wide
16 area of the preparation.

17 Morphological and functional characterization 18 of ovary in cows

19
20 The ovaries of cows are covered with a single layer of cuboidal
21 germinal epithelium. Beneath the epithelium there is albuginea of
22 dense connective tissue.



Cortex and medulla are distinguished in the ovary. Developing
follicles, atretic follicles and corpus luteum lie in the stroma of cortex.
In the outer cortex layer itself there are primary follicles, which are
surrounded by a layer of flat cells.

As developed, oocytes are gradually moving into the depth of
cortex and follicular epithelium turns from cubic to flat, and then
prismatic. Then albuginea is formed around oocytes as a product of
their metabolism, and the epithelium becomes multilayered.

The analysis of the results of cytometric studies has established the
size of follicular cells in the left ovary of the cow, which on average was
 $83.79 \pm 14.21 \mu\text{m}^2$ (from 62.8 to $122 \mu\text{m}^2$). A predominance of small
cells was identified from the linear analysis of the area of the left ovary
cytoplasm. The area of cytoplasm of the follicular epithelium of the
right ovary in cows averaged $52.85 \pm 10.69 \mu\text{m}^2$ (from 35.9 to $78 \mu\text{m}^2$).
Results of follicular epithelium studies of the right ovary indicated the
presence of three generations of follicular cells. Medium-sized cells are
dominating (Figure 3a).

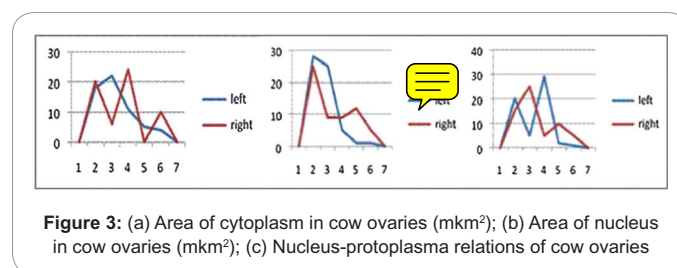
The analysis of the results of cytometric studies of the nucleus
area in left ovary has established the size of follicular cells in the
left ovary, which on average was $30.83 \pm 10.12 \mu\text{m}^2$ (from 17.5 to
 $69.9 \mu\text{m}^2$). Small nuclei are dominating. The area of nuclei of epithelial
cells in the right ovary in cows averaged $15.99 \pm 5.20 \mu\text{m}^2$ (from 8.89 to
 $26.6 \mu\text{m}^2$). The linear analysis of nucleus area revealed the presence of
a large generation of cells with left-hand modality, which indicates the
presence of the nuclei of small size. There is also one generation of large
nuclei with modality shift to the right (Figure 3b).

Indicators of nucleus-protoplasma relations of the left ovary are on
average 0.363 ± 0.07 (from 0.245 to 0.572). Linear analysis of nucleus-
protoplasma relations indicates a low functional activity of the surface
epithelium of follicles. However, part of the follicular epithelium retains
its functional activity at the medium level, as evidenced by a centrally
located modality of one of two generations of the follicular epithelium.
The nucleus-protoplasma relations of the follicular epithelium of the
right ovary in cows is 0.299 ± 0.06 (from 0.209 to 0.438). In the linear
analysis of nucleus-protoplasma relations, two cell generations were
identified, and the generation of epithelial cells with low functional
activity is dominating. One quarter of the follicular cells retains the
functional activity above average. The functional activity of the
follicular epithelium of the right ovary is lower than that in the left
ovary by 17.6% (Figure 3c).

Morpho-functional characterization of uterine horns

The wall of uterine horns is represented by three membranes: the
mucous membrane (endometrium), muscle (myometrium) and serous
(perimetrium).

After having analyzed the results of studies, it was established that
the thickness of the mucous layer of the left uterine horn averaged



1 1276.4 ± 213.86 μm. At the same time there are thinning areas up to
 2 970 μm, which are interspersed with small areas of thickened mucus
 3 layer up to 1,680 μm. The thickness of the mucous layer of the right
 4 uterine horn in cows averaged 1108.5 ± 137.99 μm (from 716 to
 5 1,303 μm). The linear analysis indicated the predominance of thickening
 6 areas of the mucus layer.

7 We have identified that the thickness of the submucosal layer of the
 8 left uterine horn also varies. On average, the value was 115.59 ± 58.08 μm.
 9 In contrast to the mucus layer, uneven thickness of the submucosal layer
 10 is less pronounced (from 23.2 to 214 μm). Linear analysis shows two
 11 equivalent generations: with extreme left and extreme right modality
 12 shift. The average thickness of the submucosal layer of the right uterine
 13 horn in cows was 108.35 ± 62.60 μm (from 17.9 to 209 μm). The linear
 14 analysis indicated the predominance of thinning areas.

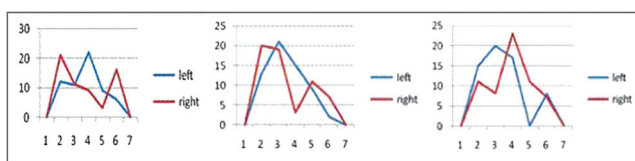
15 The muscular layer of uterine horns, that is, myometrium, consists
 16 of an internal circular and external longitudinal layers of smooth
 17 muscle fibers. These layers are separated by connective tissue, which
 18 is very rich in blood vessels and nerves – vascular layer. The thickness
 19 of the muscular layer of the left horn is uneven throughout the uterine
 20 horns. It averaged 1419.2 ± 524.92 μm (from 629 to 1,996 μm). The
 21 graphical illustration of the muscular layer thickness follows the pattern
 22 of submucosal layer thickness. The thickness of the muscular layer of
 23 the right uterine horn in cows averaged 1237.9 ± 484.74 μm (from 457
 24 to 2,000 μm). The linear analysis shows thinning of the muscular layer
 25 of the right uterine horn.

26
 27 *Morpho-functional characterization of surface epithelium*
 28 *of the mucous membrane of uterine horns*
 29

30 The cytometric studies have shown that the area of the cytoplasm of
 31 epithelial cells of the surface epithelium of the mucous membrane of the
 32 left uterine horn in cows averaged 41.28 ± 5.93 μm² (30-53.5 μm²). The
 33 linear analysis revealed a pronounced generation of cells with a central
 34 modality location. The analysis of surface epithelium of the right uterine
 35 horn in cows identified that cell size in average was 47.15 ± 17.98 μm²
 36 (from 22.1 to 76.5 μm²). The analysis of cytoplasm area identified two
 37 large cell generation of left-hand modality (Figure 4a).

38 The average area of the nucleus of epithelial cells of the left uterine
 39 horn was 12.56 ± 2.48 μm² (from 7.99 to 19.1 μm²). The linear analysis
 40 of nuclei area identified the presence of one generation of nuclei with
 41 left-hand shift (Figure 4b). The average area of nucleus of epithelial cells
 42 of the surface epithelium of the right horn in cows was 16.0 ± 7.29 μm²
 43 (from 6.44 to 29.8 μm²). The linear analysis revealed two generations.
 44 One pronounced generation of small-sized nuclei. The second generation
 45 is represented by a small number of large nuclei.

46 Nucleus-protoplasm relations of surface epithelium of the mucous
 47 membrane of the left uterine horn was 0.303 ± 0.04 (from 0.217
 48
 49



50
 51
 52
 53
 54
 55
 56
 57 **Figure 4:** (a) Area of cytoplasm of surface epithelium of uterine horns
 58 (mkm²); (b) Nucleus area of surface epithelium of the mucous membrane
 59 of uterine horns (mkm²); (c) Nucleus-protoplasm relations of surface
 60 epithelium of the mucous membrane of uterine horns

to 0.443). At the same time, two generations of epithelial cells were
 identified with different functional activity. Pronounced generation
 with left shift modality indicates the predominance of inactive cells
 in the surface epithelium. Weakly expressed generation with the
 right modality shift signifies a small number of cells retain a greater
 functional activity. Nucleus-protoplasm relations of surface epithelium
 of mucous membrane of the right uterine horn averaged 0.329 ± 0.04
 (from 0.252 to 0.408). The linear analysis of the area of nucleus-
 protoplasm relations revealed two cell generations. One of them has
 a central location. The other one, less populated cell generation, has
 a lower functional activity (Figure 4c).

Morpho-functional characterization of glandular epithelium
of uterine horns

Glandular epithelium forms numerous protrusions – uterine
 glands. The glands are of the same epithelium as in the endometrium –
 single layer, sometimes ciliated, prismatic. The glands are arranged in

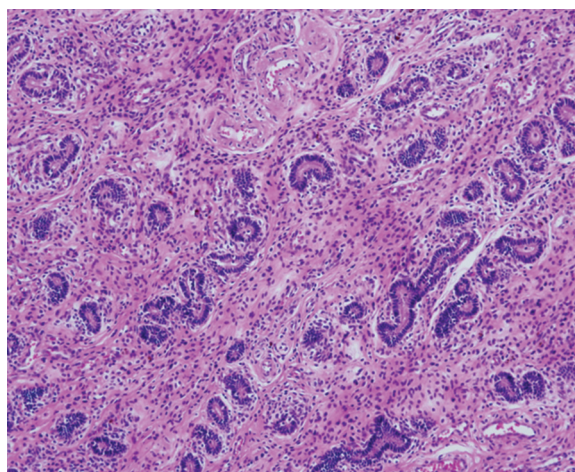


Figure 5: Glandular epithelium of the left uterine horn in cows
 (hematoxylin and eosin ×10)

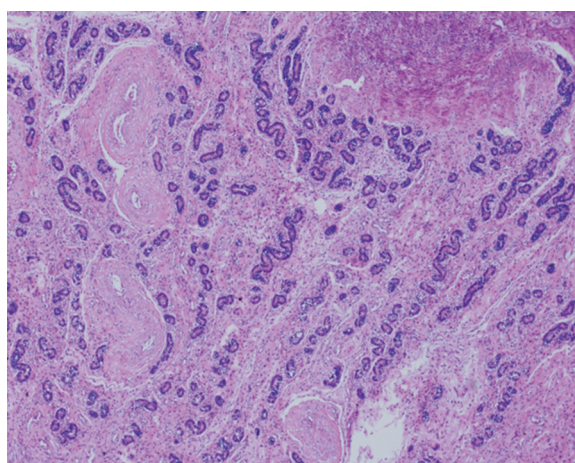


Figure 6: Glandular epithelium of the right uterine horn in cows
 (hematoxylin and eosin ×10)

parallel rows at an oblique angle to the mucosal surface and penetrate rather deeply almost to muscle (Figures 5 and 6).

Tubular-alveolar glands of uterine horns are arranged densely, irregularly in the connective tissue near the foci of inflammation. The size of adenomeres was $24.81 \pm 8.08 \mu\text{m}$. The inner diameter of the uterine glands in cows ranged from 8.84 to 43.7 μm . The analysis of studies of the inner diameter of glands found that the average value was $14.87 \pm 6.85 \mu\text{m}$. It ranged from 6.06 to 29 μm . The linear studies have identified two generations. However, glands are dominated by small-sized glands (Figure 7a).

Adenomeres of mucous membrane of the uterine horns are generally of average size, as evidenced by the central modality location. Cavity of adenomeres is filled with foamy secretion.

The average outer diameter of glands of the left uterine horn was $47.23 \pm 15.15 \mu\text{m}$ (from 26.5 to 96.3 μm). The linear analysis identified an outer diameter with left-hand shift of modality. The same value for the right uterine horn in cows was 42.32 ± 12.48 . Data range from 22.3 to 73.8 μm . Two pronounced generations were identified. Larger glands are dominating (Figure 7b).

The height of exocrine cells of the epithelium of left uterine horn ranged from 9.62 to 26.8 μm . The average value was $15.39 \pm 4.87 \mu\text{m}$, while the linear analysis indicates the presence of a pronounced generation of small exocrine cells. The average height of exocrine cells of epithelium of the right uterine horn in cows was $10.48 \pm 4.25 \mu\text{m}$ (from 5.33 to 20.1 μm). The linear analysis revealed a single pronounced generation with left-hand shift (Figure 7c).

Exocrine cells of glandular epithelium of the left uterine horn were of small size ($46.01 \pm 5.60 \mu\text{m}^2$), and their area ranged from 33.1 to 59.1 μm^2 (Figure 8a). The linear analysis revealed a pronounced generation of nuclei with a central modality location. The average size of exocrine cells of right uterine horn in cows was $63.22 \pm 23.40 \mu\text{m}^2$ (from 32.5 to 105 μm^2). The linear analysis revealed two pronounced generations of nuclei with left-hand modality location. One of them has a pronounced left-hand shift (Figure 8a).

Exocrine cells have small nuclei area averaged 13.44 ± 1.82 (from 9.81 to 16.7). The linear analysis of nuclei area identified two generations of nuclei with extreme right and the extreme left shift of modality. At the same time, there was a predominance of cells of a larger size (Figure 8b). The average area of the nucleus of glandular epithelium of the right uterine horn was 21.72 ± 11.75 (from 8.95 to 43). The linear analysis of nuclei area identified the presence of two generations. Small nuclei are dominating.

The analysis of cytometric studies of nucleus-protoplasma relations of the glandular epithelium of left uterine horn in cows identified an average of 0.282 ± 0.01 . Its functional activity varies from 0.24 to 0.319.

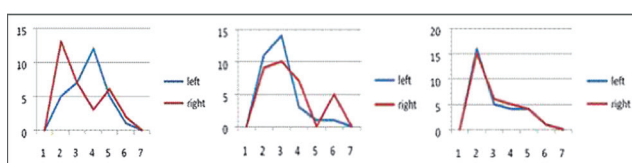


Figure 7: (a) Inner diameter of glands of uterine horns in cows (mkm); (b) Outer diameter of glands of uterine horns in cows (mkm); (c) Height of gland epithelium of uterine horns in cows (mkm)

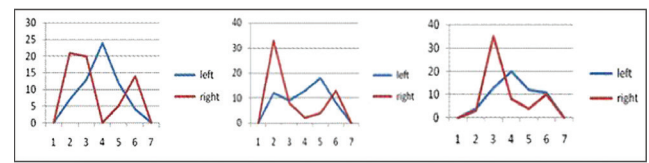


Figure 8: (a) Area of cytoplasm of glandular epithelium of uterine horns (mkm²); (b) Area of nucleus of glandular epithelium of uterine horns (mkm²); (c) Area of nucleus-protoplasma relations of glandular epithelium of left uterine horn

The linear analysis showed a large generation of cells with a central modality location. Nucleus-protoplasma relation of the epithelium of right uterine horn in cows was 0.324 ± 0.05 (from 0.246 to 0.439). Two cell generations were identified. The main portion of cells has a low functional activity (Figure 8c).

The most common cause of symptomatic infertility in cows is the functional disorders of the ovaries.

Study of the morpho-functional state of medulla with sclerosis of ovaries and uterine horns in cows gives reason to conclude that the histological and morphological changes in the uterine horns of cows are correlated with changes in the ovaries. In particular, for ovarian sclerosis, the functional activity of cells in the epithelium of uterine horns is degraded.

In the present research, we analyzed the dynamics of cytometric characteristics of glandular and surface epithelium of the uterine horns in cows with infertility due to ovarian sclerosis.

The outcomes will allow assessing the functional capacity of the mucous membrane of the uterine horns, which is necessary to assess the depth of structural changes with this pathology.

Conclusions

Left ovary usually undergoes a significant ingrowth of connective tissue. With ovarian sclerosis, despite the smaller size of the left ovary as compared to the right one, its mass exceeds that of the right ovary by 30.7%.

The number of primary follicles in the medulla of the left ovary is less than in the right one by 19.3%, and secondary follicles, on the contrary, are more in the left ovary than in the right one by 23.1%. No mature follicles were found in the left ovary, and a small amount of mature and atretic follicles were identified in the right ovary.

The area of cytoplasm and nuclei in the follicular epithelium in the left ovary exceeds the corresponding figures for the right ovary by 36.9 and 48.1%, respectively. The functional activity of the follicular epithelium of the right ovary is lower than that in the left ovary by 17.6%.

The mucous membrane of the left uterine horn with higher absolute figures of thickness has more extensive areas of thinning. Submucosal thickness in the left and right horns has no significant differences. Thickness non-uniformity in the submucosal layer of the left horn is less pronounced; predominance of submucosal thinning is identified in the right horn. The thickness of muscular layer of the left uterine horn is higher than in the right one by 12.7%. This conclusion is supported by the linear analysis.

The area of the cytoplasm and nuclei of the surface epithelium in the right horn is larger than in the left one by 12.4 and 21.5%, respectively.

1 Functional activity of the surface epithelium in the right horn is greater
2 than that in the left horn by 7.9%.

3
4 Glands of uterine horns are arranged densely, irregularly. Inner and
5 outer diameter of adenomeres in the left uterine horn is greater than in
6 the right one by 40 and 10.4%, respectively. The height of exocrine cells
7 of the left horn is greater than that in the right horn by 31.9%.

8 However, the area of cytoplasm of exocrine cells of uterine horns in
9 the left horn is smaller than in the right one by 27.2%. The size of nuclei
10 in the left horn is greater than in the right horn by 38.1%. Exocrine
11 cells of the left uterine horn are more stretched, compressed laterally,
12 have larger nuclei than exocrine cells of the right horn. The functional
13 activity of glandular epithelium of the left uterine horn is greater than
14 the corresponding figure for the right uterine horn by 12.9%.

15 The outcomes will allow assessing the functional capacity of the
16 mucous membrane of the uterine horns, which is necessary to assess
17 the depth of structural changes with this pathology.

18 Acknowledgments

19 We express our sincere gratitude to the staff of Pathological Center,
20 Lithuanian University of Health Sciences (Kaunas, Lithuania) including
21 Alius Pockevicius, Jurata Sabeckiene and Greta Cikanaviciute, and
22 a researcher at the Institute of Laser Surgery Emergency Hospital
23 (Chelyabinsk, Russia) Astakhova L.V.

24 References

- 25
26
27 1. Bazhenova NB (2001) Diagnostic and prognostic information content of
28 epithelial tissue of healthy and unhealthy reproductive system of cows: clinical
29 and morphological studies. Dissertation abstract. Saint-Petersburg, FL.
- 30 2. Mustafin RKh (2009) Pathological changes in endocrine organs of highly
31 productive cows with ovarian dysfunction. Dissertation abstract. Ufa.

- 32
33
34
35
36
37
38
39
40
41
42
43
44
45
46
47
48
49
50
51
52
53
54
55
56
57
58
59
60
3. Yepanchintseva OS (2013) Pathological and morphological changes in the
genital organs of cows with hidden endometritis. Modern problems of science
and education.
4. [Image]stics, treatment and prevention of pathologies of ovaries and oviducts in
cows: study guide, 2010. Vitebsk 3: 37.
5. Azawi OI (2008) Postpartum uterine infection in cattle. Animal Reproduction
Science 105(3-4): 187-208.
6. Chapwanya A, Meade KG, Narciandi F, Stanley P, Mee JF, *et al.* (2010)
Endometrial biopsy: a valuable clinical and research tool in bovine reproduction.
Theriogenology 73: 988-994.
7. Dmitriyeva TO (2008) Problem of productive capacity and productive longevity
of cows in the Leningrad region. International Veterinary Gazette 3: 6-8.
8. Dmitriyeva TO (2011) Synthetic β -carotene in the prevention of obstetric
pathology in highly productive cows. Veterinary Medicine 2: 42-44.
9. Dmitriyeva TO (2011) Prevention of obstetric pathology in highly productive
cows in the dry period in the spring season. Proceedings of the International
Conference on pathophysiology of animals, to commemorate the 90th
anniversary of the Department of Pathological Physiology, Federal State
Educational Institution of Higher Professional Education "St. Petersburg State
Academy of Veterinary Medicine." Saint-Petersburg, pp. 28-29.
10. Gavrylenko NN (2011) Infertility in cows in the farms of the Far Eastern Federal
District (causes and forms of infertility, diagnosis, prognosis, treatment and
prevention. Kazan.
11. Plemyashov KV, Dmitriyeva TO, Moiseyenko DO, *et al.* (2010) Carofertin.
Restoration of reproductive function in animals. Methodical recommendations.
Saint-Petersburg, p. 21.
12. Taranova LA (2000) Dynamics of morphological and functional parameters of
the endometrium of cows depending on the methods of treatment and nature
of inflammatory process in the uterus. Yekaterinburg, p. 156.
13. Volkova DV (2008) Morphometric characterization of the endometrium of cows
in normal state, with pathology and complex treatment. Peoples' Friendship
University of Russia, pp. 125-127.

Citation: Asilhanovna KM, Alekseevna TA, Mikloshevich TI, Muafik M, Albina A (2016) Analysis of Morpho-Functional Characteristics of Uterine Horns in Ovarian Sclerosis. Biol Med (Aligarh) 7(5): BM-144-16, 6 pages.

Submit your next manuscript and get the following advantages

Special features:

- 30 days rapid review process
- Quality and quick editorial, review and publication processing
- Indexing at Scopus, EBSCO, ProQuest, Gale Cengage, and Google Scholar etc
- Authors, Reviewers and Editors rewarded with online Scientific Credits
- Better discount for your subsequent articles

Submit your manuscript at: submissions@biomedonline.com

